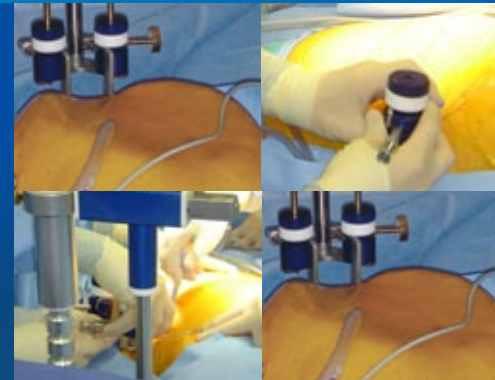


# LAPARO TENSER™



## Videos of Procedures Using LaparoTenser

- [▶ Video 1 Bariatric](#)
- [▶ Video 2 Gynecology](#)
- [▶ Video 3 Lap Chole](#)
- [▶ Video 4 Urology](#)



## Isobaric Laparoscopy

- ▶ a safe and easy way to create a large intra-abdominal operative space without pneumoperitoneum
- ▶ a proven method that eliminates the hazards of blind punctures in laparoscopy while reducing patient pain
- ▶ a totally subcutaneous method of creating a large space between the abdominal wall and viscera
- ▶ a NOTES enabling technology that provides an easy and cost effective solution to a difficult issue

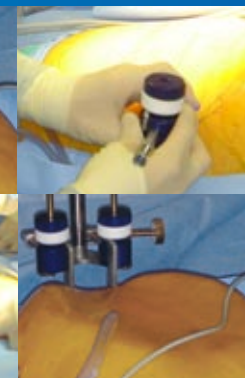
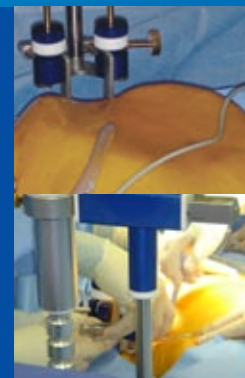MINI INVASION

MACRO EXPANSION

Safe • Easy to use • Proven • Fast • Cost Effective

# LAPARO TENSER™

## TECHNOLOGY



### Videos of Procedures Using LaparoTenser

- [▶ Video 1 Bariatric](#)
- [▶ Video 2 Gynecology](#)
- [▶ Video 3 Lap Chole](#)
- [▶ Video 4 Urology](#)


### Isobaric Video Laparoscopy Surgery

A surgical technique similar to the classic video laparoscopic surgery (pneumoperitoneum), which is performed in cavities at atmospheric pressure that is to say in cavities where there "is no free fluid at a specific pressure different from the atmospheric pressure. The cavity expansion is supported by simply using a multiple action (vertical+horizontal) retractor device (LaparoTenser).

*(Eng. Flavio Lucini, 27-02-99)*

### Low-pressure Laparoscopy

During the lifting time, if you want you can insufflate the CO2 at low pressure (4-5 mmHg) to have the extra exposition.



### Pluriplan Needles™

The thorough analysis of the abdominal tissue tensions caused by gas expansion has provided us with a mathematical model. The mathematical model enabled the design of the pluriplan needles. The Pluriplan Needles are the only subcutaneous devices with minimal invasivity, ideal to produce an intraperitoneal expansion similar to the one obtained by means of pneumoperitoneum.

## Virtual Tutorials

### ▶ Components

- Sterilization Box
- Steering Column
- Vertical Arm
- Horizontal Arm/Bariatric Arm
- Elevator Rod
- Fasteners (R)
- Holding Screw
- Tension Device
- Template for Interaxis Incision
- Pluriplan Needles
  - Small | Medium | Large (Bariatric)

### ▶ LaparoTenser Set Up

- Gynecology
- Lap Chole
- Urology
- Bariatric

# LAPARO TENSER™

## BENEFITS

### SAFE

- No Pneumoperitoneum
- No Blind Punctures
- Placed in the Subcutaneous Tissue Space

### EASY TO USE

- Simple Set Up and Use

### PROVEN

- Over 5000 Patients Successfully Treated

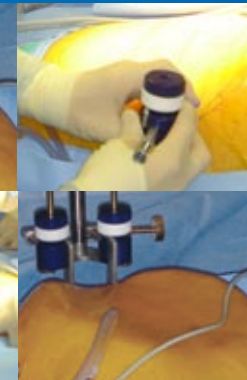
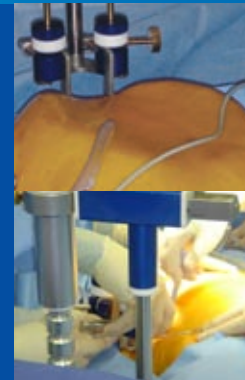### FAST

- Creates a Large Operative Space in Less Time Than a High-Flow Insufflator

### COST EFFECTIVE

- Total Sterilization of the LaparoTenser by Steam
- Possibility of Use of Standard Operative Instruments Versus Costly Disposables

### NOTES ENABLING TECHNOLOGY



## Videos of Procedures Using LaparoTenser

- ▶ Video 1 Bariatric
- ▶ Video 2 Gynecology
- ▶ Video 3 Lap Chole
- ▶ Video 4 Urology

## Background

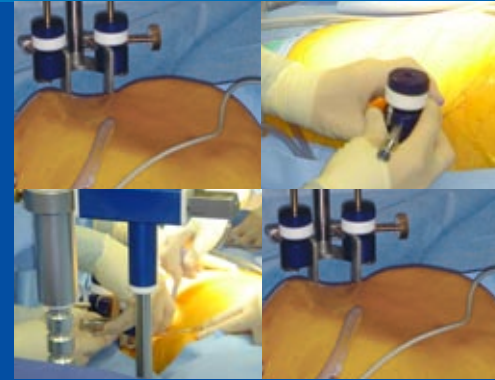


- ▶ The LaparoTenser design incorporates a mathematical model that produces maximum space with minimized contact to the patient. The LaparoTenser has been extensively used in Europe with successful treatment of thousands of patients.

Numerous peer reviewed clinical studies show the LaparoTenser as a highly favorable alternative to pneumoperitoneum in laparoscopy.



# CLINICAL STUDIES



## Videos of Procedures Using LaparoTenser

- [▶ Video 1 Bariatric](#)
- [▶ Video 2 Gynecology](#)
- [▶ Video 3 Lap Chole](#)
- [▶ Video 4 Urology](#)

- [▶ \*\*Gasless Laparoscopic Myomectomy Indications, Surgical Technique, and Advantages of a New Procedure for Removing Uterine Leiomyomas\*\*](#)  
*The Journal of Reproductive Medicine*
- [▶ \*\*Isobaric \(gasless\) laparoscopic uterine myomectomy. An overview\*\*](#)  
*European Journal of Obstetrics & Gynecology and Reproductive Biology*
  - **Comment**
  - **Author's response to comment**
- [▶ \*\*Isobaric \(gasless\) laparoscopic myomectomy during pregnancy\*\*](#)  
*Journal of Minimally Invasive Gynecology*
- [▶ \*\*Laparoscopic Myomectomy for Very Large Myomas Using an Isobaric \(Gasless\) Technique\*\*](#)  
*JSLs, Journal of the Society of Laparoendoscopic Surgeons*





Review

# Isobaric (gasless) laparoscopic uterine myomectomy An overview

Francesco Sesti <sup>a,\*</sup>, Luigi Melgrati <sup>b</sup>, Alfredo Damiani <sup>b</sup>,  
Emilio Piccione <sup>a</sup>

<sup>a</sup> *Section of Gynecology and Obstetrics, Department of Surgery, School of Medicine, Hospital University 'Tor Vergata' of Rome, Viale Oxford 81, 00133 Rome, Italy*

<sup>b</sup> *Division of Obstetrics and Gynecology, International School of Gynaecological Endoscopy, 'S. Pio X' Hospital, Via F.Nava 31, 20159 Milan, Italy*

Received 27 January 2006; received in revised form 11 March 2006; accepted 24 April 2006

---

## Abstract

The aim of this review has been to assess the usefulness and effectiveness of isobaric (gasless) laparoscopic myomectomy using a subcutaneous abdominal wall lifting system, and to evaluate the advantages and disadvantages of this technique in comparison with the conventional laparoscopic myomectomy using pneumoperitoneum. Laparoscopy using CO<sub>2</sub> is more frequently employed for small or medium-sized myomas. Furthermore, multiple myomectomies (≥3 myomas per patient) are performed rarely. Gasless laparoscopy permits the removal of large intramural myomas overcoming the difficulties associated with laparoscopic myomectomy using pneumoperitoneum. It appears to offer several advantages over conventional laparoscopy, such as elimination of the adverse effects and potential risks associated with CO<sub>2</sub> insufflation; use of conventional laparotomy instruments that facilitate several steps of the procedure; reduced operative times and costs. Indeed, this procedure associates the advantages of laparoscopy and minimal access surgery with those of using the laparotomic instruments that are more reliable for uterine closure. The only advantage of the laparoscopy with pneumoperitoneum is the tamponade effect generated by the gas on the small vessels, thus reducing intraoperative bleeding. Laparoscopic myomectomy using CO<sub>2</sub> remains the preferred minimally invasive approach for small and medium-sized myomas and when the total number of myomas removed does not exceed 2 or 3. Gasless laparoscopic myomectomy could be mainly indicated for removal of large intramural myomas (≥8 cm) and/or for multiple myomectomies (≥3 myomas per patient). Anyhow, further controlled studies are needed to evaluate entirely their respective indications. © 2006 Elsevier Ireland Ltd. All rights reserved.

*Keywords:* Uterine myomas; Isobaric gasless laparoscopy; Myomectomy; Abdominal wall lifting devices

---

## Contents

1. Introduction . . . . .	10
2. Surgical procedure . . . . .	10
2.1. Technical principles . . . . .	10
3. Clinical and surgical results . . . . .	10
3.1. Patients' characteristics . . . . .	10
3.2. Operative findings . . . . .	11
4. Discussion . . . . .	12
References . . . . .	13

---

\* Corresponding author. Tel.: +39 06 20 900 161; fax: +39 06 20 900 161.  
E-mail address: [Francesco.Sesti@uniroma2.it](mailto:Francesco.Sesti@uniroma2.it) (F. Sesti).

## 1. Introduction

Although laparoscopic myomectomy has been performed since Semm and colleagues that described the procedure in late 1970s [1–4], its role as a treatment option for symptomatic uterine fibroids has been questioned. Laparoscopic myomectomy is clearly associated with shorter hospitalization, faster recovery, less expense, less pain, less blood loss, less fever, and fewer surgical complications compared to abdominal myomectomy [5–8]. However, laparoscopic myomectomy using pneumoperitoneum is associated to a prolonged operative time, requiring greater skill and more expensive endoscopic instruments. In particular, for large intramural myomas the procedure is reputed technically difficult, with more blood loss and an elevated risk of conversion to laparotomy. Indeed, it was reported that laparoscopic myomectomy for large myomas ( $\geq 8$  cm) is hindered by several factors, such as their more difficult cleavage, the increase in operative time, the risk of perioperative bleeding [9]. Moreover, it was underlined that the total number of myomas removed should not exceed 2 or 3 [10]. Nevertheless, a small number of series on laparoscopic removal of large myomas has been published [11–13]. Generally, an analysis of the main reports on laparoscopic myomectomy demonstrates that the procedure is employed more frequently for small and medium-sized myomas ( $< 6$  cm) and rarely for multiple myomectomies ( $\geq 3$  myomas per patient) [9,14–21].

Since the more recent introduction of isobaric laparoscopy using abdominal wall lifting, the first reports on gasless laparoscopic myomectomy have been published [22,23]. This procedure, that is possible to perform also under local and regional (epidural or spinal) rather than general anesthesia, can be performed with conventional surgical instruments introduced through small abdominal incisions. This opportunity can permit to remove rapidly and safely uterine myomas.

The aim of this review has been to assess the usefulness and effectiveness of isobaric laparoscopic myomectomy using a subcutaneous abdominal wall lifting system, and to evaluate the advantages and disadvantages of this technique in comparison with the conventional laparoscopic myomectomy using pneumoperitoneum.

## 2. Surgical procedure

### 2.1. Technical principles

The surgery is performed with the patients in the Trendelenburg position up to  $30^\circ$ . Uterine cannulation is always used in order to achieve optimal exposure of the myoma. Initially, subcutaneous lifting of the anterior abdominal wall is obtained by using the Laparotenser system (Lucini Surgical Concept, Milan, Italy), such as already described [23]. Two curved ‘pluriplan’ needles with blunt tips are introduced subcutaneously through two very small (2 mm) pubic skin incisions. They are suspended from a mechanical arm attached to a rigid pillar, and the arm is

then elevated as far as necessary to obtain optimal exposure. Primary access is achieved by insertion of a 10–11-mm trocar through a vertical intraumbilical incision after lifting the abdominal wall with the Laparotenser. Under direct visualization, two lower incisions lateral to the rectus muscles are performed without using trocars. On the right side, the lower incision is 15 mm; it is 10 mm on the left. Conventional laparotomy instruments are employed through the larger incision. The only laparoscopic instruments used are the irrigation–suction cannula and the bipolar cautery. The ancillary right access permits the insertion of  $\leq 3$  instruments; the left permits insertion of two instruments.

Hysterotomy is performed transversally on the principal myoma along its maximum diameter using a low voltage electrode (monopolar scissors or hook). Hemostasis of the smallest intramyometrial vessels is achieved progressively using precise bipolar coagulation. Sharp dissection with Metzenbaum scissors allows the avascular cleavage plane to be created, separating the tumour and the surrounding myometrium. Enucleation is then executed by traction on the myoma with two strong tenaculum clamps, together with countertraction on the uterus with narrow ring forceps that facilitates dissection. The myoma is then pulled hard toward the anterior abdominal wall or upward. The connective tracts adhering to the myoma are coagulated and sectioned with conventional scissors. Similarly, the blood major vessels supplying the myoma are clamped with conventional instruments and coagulated. The bed of myomectomy is usually free of bleeding because care has been taken in achieving hemostasis.

The uterine defect is repaired, using a conventional long needle holder, in two continuous layers with 1 Monocryl (poliglecaprone 25; Ethicon Inc., Bruxelles, Belgium), a synthetic adsorbable, monofilament suture, 135 cm long, mounted on a 39-mm curved needle with atraumatic tip. The suturing commences at the right superior edge of the hysterotomy area and proceeds into myometrium towards the opposite side. At level of the left inferior edge, the second layer of continuous serosa-to-serosa suturing is then completed from the left side toward the right one up to the apex. At level of the right apex, intracorporeal knot tying is used to secure the suture ends with the aid of the index finger, introduced through the ancillary right access.

The myomas are extracted from the abdominal cavity. The myoma is grasped by two opposite tenaculum clamps and converted into thin strips of tissue using conventional scissors or scalpel. The myoma strips are removed through the ancillary right port.

## 3. Clinical and surgical results

### 3.1. Patients’ characteristics

Three series of patients were reviewed. In the first, 279 consecutive women were undergone gasless laparoscopic

myomectomy [23]. Inclusion criteria were the presence of at least one symptomatic subserosal or intramural myoma measuring  $>30$  mm. The main symptoms were pain, lower abdominal discomfort, menometrorrhagia, abnormal uterine bleeding, and progressively increasing myoma size, evaluated by ultrasound.

In the second series, 63 consecutive patients with at least one large symptomatic subserosal or intramural uterine myoma  $\geq 8$  cm underwent an isobaric laparoscopic myomectomy (unpublished data). The major clinical indications for surgery included: pelvic pain in 13 women, lower abdominal discomfort in four, abnormal uterine bleeding in 12, menometrorrhagia in 19, infertility in seven, and pressure symptoms by pelvic mass in eight. Some women exhibited more than one symptom.

In the third series, 24 consecutive women with at least one large symptomatic subserosal or intramural uterine myoma  $\geq 10$  cm underwent an isobaric laparoscopic myomectomy [24]. The indications for surgery included pelvic pain, lower abdominal discomfort, abnormal uterine bleeding, menometrorrhagia, infertility and pressure symptoms by pelvic mass. Some women exhibited more than one indication. Fifteen women wished preserve the fertility because they wanted a child, the remaining 11 preferred in any case to preserve the uterus.

The preoperative evaluation comprised: hemoglobin and hematocrit levels, abdominal and transvaginal ultrasonography, hysteroscopic examination of the uterine cavity. Gonadotropin releasing hormones agonists (GnRH-a) were prescribed only when anemia and low hematocrit due to excessive uterine bleeding were present. Treatment consisted of intramuscular administration of depot triptorelin (Decapeptyl<sup>®</sup>; Ipsen Pharma Biotech, Signes, France) every 4 weeks for 3 months.

### 3.2. Operative findings

In the first series, gasless laparoscopic myomectomy using the Laparotenser system was successful in all 279 consecutive patients. The number of myomas removed from each patient ranged from 1 to 8 (average, 3.1). In 59 cases (21.1%) multiple myomectomy was performed. The location of the major myoma was intramural in 118 patients (42.3%), subserosal in 161 (57.7%). The size of the dominant myoma varied from 3 to 12 cm (average 5.9). The site of the major myoma was anterior in 71 patients, fundal in 106, and posterior in 102. The mean blood loss was 102 ml (range, 40–320 ml). No transfusions were required. The mean operating time was 73 min (range, 35–145). The mean inserting Laparotenser time was 5 min (range, 3–8). The hospital stay was 2–5 days (average, 2.6). In 242 patients the procedure was performed under general anesthesia. The remaining 57 patients preferred a peridural anesthesia. In no case, a conversion to general anesthesia was necessary. There were no anesthesiologic complications. The postoperative complications observed were:

febrile morbidity ( $>38$  °C) without infectious complications in three cases, and a subcutaneous hematic infiltration in one patient that regressed spontaneously. No injury to epigastric vessels was observed. No conversion to laparotomy was necessary. During the 6 months' postoperative follow-up, the main symptoms complained from the patients prior to surgery disappeared.

In the second series, isobaric laparoscopic myomectomy was successfully performed on all 63 patients. The number of myomas removed from each patient ranged from 1 to 7 (mean, 3.6). In 16 cases (25.4%) multiple myomectomy was performed. The location of the principal myoma was intramural in 19 patients (30.2%) and subserosal in 44 (69.8%). The size of the dominant myoma varied from 8 to 20 cm (mean, 11.0 cm). The site of the major myoma was anterior in 22 patients, fundal in 23, and posterior in 28. The mean blood loss was 143 ml (range, 50–450 ml). No transfusions were required. The mean operating time was 72 min (range, 50–150 min). The mean inserting Laparotenser time was 3.5 min (range, 2–5). The hospital stay was 2–5 days (mean, 2.9 days). In 48 patients the procedure was performed under general anaesthesia. The remaining 15 patients preferred an epidural anaesthesia. In no case, a conversion to general anaesthesia was necessary. There were no anesthesia complications. No intraoperative complication occurred and there was no case returning to theatre. Postoperative complications included febrile morbidity ( $>38$  °C) without infectious complications in five cases. No injury to epigastric vessels was observed. No conversion to laparotomy was necessary. No patient complained significant abdominal postoperative discomfort as a result of the abdominal wall lifting. At the 12-month postoperative follow-up, the main symptoms prior to surgery had all resolved. Ultrasound findings showed that there were no recurrence or residual fibroids following surgery.

In the third series, isobaric laparoscopic myomectomy was successfully performed in all 24 consecutive patients. The number of myomas removed from each patient ranged from 1 to 4 (average, 2.3). In five cases (20.8%) multiple myomectomy was performed. The location of the principal myoma was intramural in 10 patients (41.6%), subserosal in 14 (58.3%). The size of the dominant myoma varied from 10 to 20 cm (average, 11.0 cm). The site of the major myoma was anterior in eight patients, fundal in nine, and posterior in seven. The median postoperative drop hemoglobin was 2.8 g/dl (range, 2.3–4.3 g/dl). No transfusions were required. The mean operating time was 93 min (range, 55–150 min). The mean inserting Laparotenser time was 3.5 min (range, 2–5). The hospital stay was 1–3 days (average, 1.9 days). No significant operative benefit (reduced blood loss during surgery, lower operative time) was found in those cases where gonadotropin therapy was administered. No intraoperative complication occurred and there was no repeat operation. Postoperative complications observed were only fever ( $>38$  °C) in five cases. Fever regressed in 1–3 days by antibiotic and NSAID adminis-

tration. No infectious complications (urinary tract, endometritis, pelvi-peritonitis) occurred. No injury to epigastric vessels was observed. No conversion to laparotomy neither hysterectomy was necessary. There were no anesthesia complications. No patient complained significant abdominal postoperative discomfort, secondary to the abdominal lifting. Right shoulder pain, a common finding after pneumoperitoneum, was observed in no patient. No postoperative herniation was found. At the 12-month postoperative follow-up, the main symptoms prior to surgery had disappeared.

#### 4. Discussion

The review of the major and more recent reports about laparoscopic myomectomy (Table 1) demonstrates that the procedure with pneumoperitoneum is employed more frequently for small or medium-sized myomas [9,14–21]. Furthermore, multiple myomectomies ( $\geq 3$  myomas per patient) are performed rarely [8,9,13–21,25]. In fact, it is considered as a difficult procedure, requiring a highly skilled endoscopic surgeon [26]. Dubuisson and Chapron [10] have suggested that the myomas should be not exceed 8 cm maximum in size, because their cleavage is more difficult, the operating time increases, the risk of perioperative bleeding is elevated [9]. Moreover, it was noted that the risk of conversion to laparotomy is higher when the myoma measures more than 50 mm, its localization is intramural or anterior, and in cases of preoperative use of GnRH-agonists [27].

Hence, large intramural myomas are usually removed by laparotomy. To overcome these difficulties associated with laparoscopic myomectomy using pneumoperitoneum and to preserve the advantages of the minimally access surgery, isobaric gasless laparoscopic myomectomy has been

developed [22]. In accordance with our first article [23], a subsequent series confirmed that gasless laparoscopic myomectomy permits the removal of large myomas through a minimally access procedure [24]. The operation was completed in all patients. No conversion to laparotomy was necessary. All the clinical outcomes analysed (operating time, blood loss, hospital stay) showed favourable results.

These satisfactory findings can be explained by the advantages of gasless laparoscopy over the conventional laparoscopy using pneumoperitoneum. First, the adverse effects and potential risks of CO<sub>2</sub> insufflation are eliminated. Second, because peritoneal cavity does not need to be sealed airtight, conventional laparotomy instruments, such as tissue clamps, tenaculum clamps, needle holders, scalpels, scissors can be utilized. This facilitates several steps of the procedure. For example, enucleation of the myoma with tenaculum clamps exerting countertraction on the uterine edge with narrow ring forceps is simple and quick. One of the main advantages is the uterine repair, which in laparoscopy with pneumoperitoneum is usually bothersome and protracted for the difficulties associated with intracorporeal suture techniques. Instead, applying the conventional curved needle deeply into the myometrium of the hysterotomy area with the laparotomy needle holder is trouble-free and fast. In this manner, a double-layer continuous closure can be quickly performed. The first layer is passed deeply through the myometrium whereas the second is a continuous serosa-to-serosa suturing. Intracorporeal knot tying is used to secure the suture ends with the aid of the index finger, introduced through the ancillary right access. Therefore, this closure results in optimal haemostasis and strength of the uterine scar.

A third advantage is the reduction of the operative costs. Expensive laparoscopic instruments are not needed. In addition, the operating times are shorter because an optimal view

Table 1  
Comparison between the major reports on laparoscopic myomectomy

Authors	Abdominal distension	Nr. of patients	Mean myoma size (cm)	Mean number of myomas per patient	Mean operating time (min)	Conversion to laparotomy (%)
Daraï et al. [8]	Pneumoperitoneum	70	6.7	1.7	NR	41.4
Dubuisson et al. [9]	Pneumoperitoneum	407	5.6	1.8	128	2.9
Sinha et al. [13]	Pneumoperitoneum	51	698.47 <sup>a</sup>	1.53	136.67	1.9
Mettler et al. [14]	Pneumoperitoneum	482	4.0	2.9	100	NR
Reich [15]	Pneumoperitoneum	109	5.0	1.1	NR	NR
Seinera et al. [16]	Pneumoperitoneum	54	4.2	NR	90	1.8
Ribeiro et al. [17]	Pneumoperitoneum	28	6.0	1.0	NR	0.0
Rossetti et al. [18]	Pneumoperitoneum	41	5.4	2.2	40–240 (range)	4.9
Landi et al. [19]	Pneumoperitoneum	268	NR	2.8	100	0.0
Fanfani et al. [20]	Pneumoperitoneum	93	5.6	1.4	62.3	0.0
Holub et al. [21]	Pneumoperitoneum	81 <sup>b</sup>	6.0	2.51	74.49	0.0
Chang et al. [22]	Intraperitoneal lifting	14	454 g <sup>a</sup>	1.0	104	0.0
Damiani et al. [23]	Subcutaneous lifting	279	5.9	3.1	73	0.0
Damiani et al. [24]	Subcutaneous lifting	24	11.0	2.3	93	0.0
Seracchioli et al. [25]	Pneumoperitoneum	66	7.0	2.9	100	4.3
Damiani et al. (unpublished data)	Subcutaneous lifting	63	11.0	3.6	72	0.0

NR: not reported.

<sup>a</sup> Mean weight.

<sup>b</sup> In 54 cases, laparoscopic myomectomy combined with uterine artery dissection; in 19 cases, laparoscopic-assisted myomectomy.



can be maintained during irrigation–suction, the repair of the uterine defect is less time consuming and myoma morcellation by scissors or scalpel is faster. Indeed, this procedure associates the advantages of laparoscopy and minimal access surgery with those of using the laparotomic instruments that are more reliable for uterine closure. In fact, when performing laparoscopic myomectomy, particular care must be given to the uterine closure, because a meticulous repair of the myometrium is essential to minimize the risk of uterine rupture during a subsequent pregnancy, labor and delivery. The only advantage of the laparoscopy with pneumoperitoneum is the tamponade effect generated by the gas on the small vessels, thus reducing intraoperative bleeding.

However, some laparoscopists are worried about the increased postoperative pain, the need for additional abdominal incisions, the time required for the assembly of the abdominal wall lifting system. But, in the examined series no patient complained of significant abdominal postoperative discomfort, secondary to the abdominal wall lifting. The additional suprapubic skin incisions required for the subcutaneous introduction of the two curved needles with blunt tips of the Laparotenser are very small (2 mm) and need no suturing. Lastly, the mean time taken to assemble the Laparotenser was just 3.5 min.

Other reports were published on the use of abdominal wall lifting devices for gasless laparoscopic surgery [22,28–32]. Problems inherent in their use included suboptimal exposure in pelvic surgery because of a “tenting” effect and possible ischemic injury to the abdominal wall muscles from the retractor. Another kind of devices consisted of subcutaneous long wires [33–35]. The Laparotenser utilizes this concept and provides subcutaneous lifting which avoids muscle injury and gives less ‘tenting’ effect. In the analysed studies [23,24], operative exposure was always as optimal as that achieved by pneumoperitoneum, in contrast to that observed by Chang et al. [22] using an intraperitoneal lifting system. Moreover, this device was employed also during pregnancy, when myomectomy becomes inevitable for the removal of symptomatic leiomyomas, such as demonstrated by the first report of isobaric (gasless) laparoscopic myomectomy at the second trimester of gestation [36].

In conclusion, this review shows that gasless laparoscopic myomectomy for removal of large myomas using a subcutaneous lifting system is feasible and safe. It appears to offer several advantages over laparoscopy with pneumoperitoneum, such as elimination of the adverse effects and potential risks associated with CO<sub>2</sub> insufflation; use of conventional laparotomy instruments that facilitate several steps of the procedure; reduced operative times and costs. Indeed, this procedure associates the advantages of laparoscopy and minimal access surgery with those of using the laparotomic instruments that are more reliable for uterine closure. It is clear that laparoscopic myomectomy using CO<sub>2</sub> remains the preferred minimally invasive approach for small and

medium-sized myomas and when the total number of myomas removed does not exceed 2 or 3. Therefore, gasless laparoscopic myomectomy could be mainly indicated for removal of large intramural myomas ( $\geq 8$  cm) and/or for multiple myomectomies ( $\geq 3$  myomas per patient). Anyhow, further controlled studies are needed to evaluate entirely their respective indications.

## References

- [1] Semm K. Pelvic surgery in gynecology. *Geburtsh Frauenheilk* 1977;37:909–20.
- [2] Semm K. Tissue-puncher and loop-ligation – new aids for surgical therapeutic pelviscopy (laparoscopy) – endoscopic intraabdominal surgery. *Endoscopy* 1978;10:119–24.
- [3] Semm K. New methods of pelviscopy (gynecologic laparoscopy) for myomectomy, ovariectomy, tubectomy and adnectomy. *Endoscopy* 1979;11:85–93.
- [4] Semm K, Mettler L. Technical progress in pelvic surgery via operative laparoscopy. *Am J Obstet Gynecol* 1980;138:121–7.
- [5] Mais V, Ajossa S, Guerriero S, Mascia M, Solla E, Melis GB. Laparoscopic versus abdominal myomectomy: a prospective, randomised trial to evaluate benefits in early outcome. *Am J Obstet Gynecol* 1996;175:654–8.
- [6] Seracchioli R, Rossi S, Govoni F, et al. Fertility and obstetric outcome after laparoscopic myomectomy of large myomata: a randomised comparison with abdominal myomectomy. *Hum Reprod* 2000;15:2663–8.
- [7] Rossetti A, Sizzi O, Soranna L, Cucinelli F, Mancuso S, Lanzone A. Long-term results of laparoscopic myomectomy: recurrence rate in comparison with abdominal myomectomy. *Hum Reprod* 2001;16:770–4.
- [8] Darai E, Deval B, Darles C, Benifla JL, Guglielmina JN, Madelenat P. Myomectomie: coelioscopie ou laparotomie. *Contracept Fertil Sex* 1996;24:751–6.
- [9] Dubuisson J-B, Fauconnier A, Babaki-Fard K, Chapron C. Laparoscopic myomectomy: a current view. *Hum Reprod Update* 2000;6:588–94.
- [10] Dubuisson JB, Chapron C. Laparoscopic myomectomy today. A good technique when correctly indicated. *Hum Reprod* 1996;11:934–5.
- [11] Adamian LV, Kulakov VI, Kiselev SI, Murashko AV. Laparoscopic myomectomy in treatment of large myomas. *J Am Assoc Gynecol Laparosc* 1996;3(Suppl 4):S1.
- [12] Stringer NH. Laparoscopic myomectomy in African–American women. *J Am Assoc Gynecol Laparosc* 1996;3:375–81.
- [13] Sinha R, Hegde A, Warty N, Patil N. Laparoscopic excision of very large myomas. *J Am Assoc Gynecol Laparosc* 2003;10:461–8.
- [14] Mettler L, Alvarez-Rodas E, Semm K. Myomectomy by laparoscopy: a report of 482 cases. *Gynaecol Endosc* 1995;4:259–64.
- [15] Reich H. Laparoscopic myomectomy. *Obstet Gynecol Clin N Am* 1995;22:757–80.
- [16] Seiner P, Arisio R, Decko A, Farina C, Crana F. Laparoscopic myomectomies: indications, surgical technique and complications. *Hum Reprod* 1997;12:1927–30.
- [17] Ribeiro SC, Reich H, Rosenberg J, Guglielminetti E, Vidali A. Laparoscopic myomectomy and pregnancy outcome in infertile patients. *Fertil Steril* 1999;71:571–4.
- [18] Rossetti A, Sizzi O, Soranna L, Cucinelli F, Mancuso S, Lanzone A. Long-term results of laparoscopic myomectomy: recurrence rate in comparison with abdominal myomectomy. *Hum Reprod* 2001;16:770–4.
- [19] Landi S, Zoccolletti R, Ferrari L, Minelli L. Laparoscopic myomectomy: technique, complications, and ultrasound scan evaluations. *J Am Assoc Gynecol Laparosc* 2001;8:231–40.

- [20] Fanfani F, Fagotti A, Bifulco G, Ercoli A, Malzoni M, Scambia G. A prospective study of laparoscopy versus minilaparotomy in the treatment of uterine myomas. *J Minim Invas Gynecol* 2005;12:470–4.
- [21] Holub Z, Jabor A, Lukac J, Kliment L, Urbanek S. Laparoscopic myomectomy with lateral dissection of the uterine artery. *JLS* 2005;9:447–53.
- [22] Chang FH, Soong YK, Cheng PJ, et al. Laparoscopic myomectomy of large symptomatic leiomyoma using airlift gasless laparoscopy: a preliminary report. *Hum Reprod* 1996;11:1427–32.
- [23] Damiani A, Melgrati L, Marziali M, Sesti F. Gasless laparoscopic myomectomy. Indications, surgical technique and advantages of a new procedure for removing uterine leiomyomas. *J Reprod Med* 2003;48:792–8.
- [24] Damiani A, Melgrati L, Marziali M, Sesti F, Piccione E. Laparoscopic myomectomy for very large myomas using an isobaric (gasless) technique. *JLS* 2005;9:434–8.
- [25] Seracchioli R, Rossi S, Govoni F, et al. Fertility and obstetric outcome after laparoscopic myomectomy of large myomata: a randomised comparison with abdominal myomectomy. *Hum Reprod* 2000;12:2663–8.
- [26] Nezhat F, Seidman DS, Nezhat C, Nezhat CH. Laparoscopic myomectomy today. Why, when and for whom? *Hum Reprod* 1996;11:933–4.
- [27] Dubuisson J-B, Fauconnier A, Fourchette V, Babaki-Fard K, Coste J, Chapron C. Laparoscopic myomectomy: predicting the risk of conversion to an open procedure. *Hum Reprod* 2001;16:1726–31.
- [28] Banting S, Shimi S, Vander Velpen G, Cuschieri A. Abdominal wall lift. Low-pressure pneumoperitoneum laparoscopic surgery. *Surg Endosc* 1993;7:57–9.
- [29] Brams DM, Cardoza M, Smith RS. Laparoscopic repair of traumatic gastric perforation using a gasless technique. *J Laparoendosc Surg* 1993;3:587–91.
- [30] Gazayerli MM. The Gazayerli endoscopic retractor model 1. *Surg Laparosc Endosc* 1991;1:98–100.
- [31] Smith RS, Fry WR, Tsoi EK, et al. Gasless laparoscopy and conventional instruments. The next phase of minimally invasive surgery. *Arch Surg* 1993;128:1102–7.
- [32] Weaver DW. Gasless laparoscopy for complex surgical procedures. *Int Surg* 1994;79:314–6.
- [33] Angelini L, Lirici MM, Papaspyropoulos V, Sossi FL. Combination of subcutaneous abdominal wall retraction and optical trocar to minimize pneumoperitoneum-related effects and needle and trocar injuries in laparoscopic surgery. *Surg Endosc* 1997;11:1006–9.
- [34] Hashimoto D, Nayeem SA, Kajiwarra S, Hoshino T. Abdominal wall lifting with subcutaneous wiring: an experience of 50 cases of laparoscopic cholecystectomy without pneumoperitoneum. *Surg Today* 1993;23:786–90.
- [35] Vezakis A, Davides D, Gibson JS, et al. Randomized comparison between low-pressure laparoscopic cholecystectomy and gasless laparoscopic cholecystectomy. *Surg Endosc* 1999;13:890–3.
- [36] Melgrati L, Damiani A, Franzoni G, Marziali M, Sesti F. Isobaric (gasless) laparoscopic myomectomy during pregnancy. *J Minim Invas Gynecol* 2005;12:379–81.

Available online at [www.sciencedirect.com](http://www.sciencedirect.com)European Journal of Obstetrics & Gynecology and  
Reproductive Biology xxx (2007) xxx–xxx[www.elsevier.com/locate/ejogrb](http://www.elsevier.com/locate/ejogrb)

## LETTER TO THE EDITOR—COMMENT

**Comment on “Isobaric (gasless) laparoscopic uterine myomectomy—An overview” [Eur. J. Obstet. Gynecol. Reprod. Biol. 129 (2006) 9–14]<sup>\*</sup>**

To the Editor,

We read with interest Sesti's review [1] on gasless laparoscopic uterine myomectomy and commend these authors' efforts. However, certain issues need to be clarified:

1. The authors opine that this procedure can be performed under local and regional (epidural or spinal) rather than general anesthesia. However, general anesthesia with muscle paralysis and tracheal intubation remains the preferred technique for most laparoscopic procedures [2]. Shorter laparoscopic procedures such as diagnostic laparoscopy, pain mapping, laparoscopy for infertility and tubal ligation can be performed under local or regional anesthesia [3].
2. The authors did not mention whether or not the CO<sub>2</sub> gas stopcock to be kept open to relieve negative intra-abdominal pressure, as soon as the vented instrument tip enters the sealed peritoneal space. It is postulated that the viscera fall away from their parietal apposition prior to contact with advancing sharp trocar [4,5]. When the abdominal wall is lifted with the Laparotenser, space will be created between the abdominal wall and viscera. This space will be occupied by atmospheric gas, which contains oxygen. Electrocoagulation in the presence of oxygen raises the possibility of electrical burns.
3. The authors suggested the use of tenaculum clamps, scissors or scalpel for removal of the myoma. The option of electromechanical morcellation facilitates easy removal of the myoma and significantly saves time [6,7].
4. Among the disadvantages of laparoscopic myomectomy using CO<sub>2</sub>, the authors mention that cleavage is more

difficult if the myoma exceeds 8 cm in size. Such a problem also exists with gasless laparoscopy.

5. It is not clear why laparoscopic myomectomy using CO<sub>2</sub> is preferred over gasless laparoscopic myomectomy when the total number of myomas does not exceed 2 or 3.

We therefore seek their clarification and hope further discussion and suggestion will contribute to advancement and the popularity of this technique amongst laparoscopists.

**References**

- [1] Sesti F, Melgrati L, Damiani A, Piccione E. Isobaric (gasless) laparoscopic uterine myomectomy—an overview. *Eur J Obstet Gynecol Reprod Biol* 2006;129:9–14.
- [2] Song D, Joshi GP, White PF. Fast-track eligibility after ambulatory anesthesia: a comparison of desflurane, sevoflurane, and propofol. *Anesth Analg* 1998;86:267–73.
- [3] Collins LM, Vaghadia H. Regional anesthesia for laparoscopy. *Anesthesiol Clin North Am* 2001;19:43–56.
- [4] Dingfelder JR. Direct laparoscope trocar insertion without prior pneumoperitoneum. *Obstet Gynecol* 1978;21:45–7.
- [5] Byron JW, Markenson G, Miyazawa K. A randomized comparison of Veress needle and direct trocar insertion for laparoscopy. *Surg Gynecol Obstet* 1993;177(3):259–62.
- [6] Carter JE, McCarus S. Time savings using the steiner morcellator in laparoscopic myomectomy. *J Am Assoc Gynecol Laparosc* 1996;(4, Suppl):S6.
- [7] Carter JE, McCarus SD. Laparoscopic myomectomy. Time and cost analysis of power vs. manual morcellation. *J Reprod Med* 1997;42(7): 383–8.

Niraj Nilkanthrao Mahajan  
Padhar Hospital Betul,  
Madhyapradesh, India  
E-mail address: [nirajdr@hotmail.com](mailto:nirajdr@hotmail.com)

22 November 2006

DOI of original article: [10.1016/j.ejogrb.2006.12.018](https://doi.org/10.1016/j.ejogrb.2006.12.018).

0301-2115/\$ – see front matter © 2007 Elsevier Ireland Ltd. All rights reserved.  
doi:[10.1016/j.ejogrb.2006.12.019](https://doi.org/10.1016/j.ejogrb.2006.12.019)

Please cite this article in press as: Mahajan Niraj Nilkanthrao, Comment on “Isobaric (gasless) laparoscopic uterine myomectomy—An overview” [Eur. J. Obstet. Gynecol. Reprod. Biol. 129 (2006) 9–14], *Eur. J. Obstet. Gynecol* (2007), doi:[10.1016/j.ejogrb.2006.12.019](https://doi.org/10.1016/j.ejogrb.2006.12.019)

Available online at [www.sciencedirect.com](http://www.sciencedirect.com)European Journal of Obstetrics & Gynecology and  
Reproductive Biology xxx (2007) xxx–xxx[www.elsevier.com/locate/ejogrb](http://www.elsevier.com/locate/ejogrb)

## LETTER TO THE EDITOR—RESPONSE TO COMMENT

**Authors' Response to Comment on "Isobaric (gasless) laparoscopic uterine myomectomy—An overview" [Eur. J. Obstet. Gynecol. Reprod. Biol. 129 (2006) 9–14]**

Dear Editor,

We are grateful to Dr. Mahajan for commenting on our review and requesting elucidation on isobaric (gasless) laparoscopic myomectomy. Regarding his first question, we specify that in our first series of patients, 57 out of 279 women preferred peridural anesthesia. In no case was a conversion to general anesthesia necessary. There were no anesthesiologic complications. Indeed, any (peripheral or general) anesthetic technique can be employed in isobaric laparoscopic procedures, as in "open" surgery, because there is no pneumoperitoneum.

In relation to the second issue, direct trocar insertion without previous pneumoperitoneum was reported to be a safe alternative to Veress needle insertion [1]. We choose to insert it just caudally to the ribs on the left side, which prevents the tissues from collapsing and allows separation of the abdominal wall from the viscera. In addition, the skin incision must be large enough to allow easy passage of the trocar through the skin to avoid forceful entry. In our practice, we did not register any complication associated with the direct insertion of the umbilical trocar. Nevertheless, injuries to intraabdominal structures, related to blind insertion of the Veress needle and the first trocar, continue to be a common, yet potentially avoidable complication of laparoscopy [2]. As a result, many surgeons have altered their technique by performing a minilaparotomy to position the first trocar safely. However, bowel injuries also have been reported with the use of this "open" technique. For these reasons, we now use optical bladeless access trocars to decrease the risk of injury to intraabdominal structures, because they allow the surgeon to visualize abdominal wall layers during placement [3].

As regards possible electrical burns, we never observed this complication. The risk of electric injuries in isobaric laparoscopy would be the same as in open surgery, where you work in presence of atmospheric gas.

The use of electrical morcellators facilitates the removal of myomas, but their costs are higher than scalpel or scissors.

Actually, surgical technique for enucleation of the myomas is analogous to laparotomy. Traction on the myomas is executed with two strong laparotomic tenaculum clamps, together with countertraction on the uterus with narrow ring laparotomic forceps that facilitates dissection. The myoma is pulled hard toward the anterior abdominal wall or upward. It is clear that the use of conventional laparotomy instruments permits a stronger grasping and an improved mobilisation of the myomas than laparoscopic instruments.

Finally, in our opinion laparoscopic myomectomy using CO<sub>2</sub> remains the preferred approach for small and medium-sized myomas and when the total number of myomas removed does not exceed 2 or 3 because it is less invasive than isobaric laparoscopy, where the ancillary right port is slightly greater (15 mm) and two very small (2 mm) additional skin incisions on the pubis are needed for the insertion of the subcutaneous needles of the lifting device. Therefore, we believe that gasless laparoscopic myomectomy could be mainly an alternative to minilaparotomy for removal of large intramural myomas and/or for multiple myomectomies ( $\geq 3$  myomas per patient), even if further controlled studies are needed to confirm it.

**References**

- [1] Gunenc MZ, Yesildaglar N, Bingol B, Onalan G, Tabak S, Gokmen B. The safety and efficacy of direct trocar insertion with elevation of the rectus sheath instead of the skin for pneumoperitoneum. *Surg Laparosc Endosc Percutan Tech* 2005;15:80–1.
- [2] Catarci M, Carlini M, Gentileschi P, Santoro E. Major and minor injuries during the creation of pneumoperitoneum: a multicenter study on 12,919 cases. *Surg Endosc* 2001;15:566–9.
- [3] Berch BR, Torquati A, Lutfi RE, Richards WO. Experience with the optical access trocar for safe and rapid entry in the performance of laparoscopic gastric bypass. *Surg Endosc* 2006;20:1238–41.

Francesco Sesti\*

*Section of Gynecology and Obstetrics,  
Department of Surgery, School of Medicine,  
Hospital University 'Tor Vergata' of Rome,  
Viale Oxford 81, 00133 Rome, Italy*

DOI of original article: [10.1016/j.ejogrb.2006.12.019](https://doi.org/10.1016/j.ejogrb.2006.12.019).0301-2115/\$ – see front matter © 2007 Elsevier Ireland Ltd. All rights reserved.  
doi:[10.1016/j.ejogrb.2006.12.018](https://doi.org/10.1016/j.ejogrb.2006.12.018)

Please cite this article in press as: Sesti Francesco et al., Authors' Response to Comment on "Isobaric (gasless) laparoscopic uterine myomectomy—An overview" [Eur. J. Obstet. Gynecol. Reprod. Biol. 129 (2006) 9–14], *Eur. J. Obstet. Gynecol.* (2007), doi:[10.1016/j.ejogrb.2006.12.018](https://doi.org/10.1016/j.ejogrb.2006.12.018)



Luigi Melgrati  
Alfredo Damiani

*Division of Obstetrics and Gynecology,  
International School of Gynaecological Endoscopy,  
'S. Pio X' Hospital, Via F. Nava 31, 20159 Milan, Italy*

Emilio Piccione

*Section of Gynecology and Obstetrics,  
Department of Surgery, School of Medicine,*

*Hospital University 'Tor Vergata' of Rome, Viale Oxford 81,  
00133 Rome, Italy*

\*Corresponding author. Tel.: +39 06 20 902 921;  
fax: +39 06 20 902 921

E-mail address: [Francesco.Sesti@uniroma2.it](mailto:Francesco.Sesti@uniroma2.it)  
(F. Sesti)

13 December 2006

# Laparoscopic Myomectomy for Very Large Myomas Using an Isobaric (Gasless) Technique

Alfredo Damiani, MD, Luigi Melgrati, MD, Massimiliano Marziali, MD,  
Francesco Sesti, MD, Emilio Piccione, MD

## ABSTRACT

**Objectives:** Laparoscopic myomectomy using pneumoperitoneum for large myomas ( $\geq 8$  cm) is hindered by several factors, such as the increased operative time, the risk of perioperative bleeding, and the risk of conversion to laparotomy. With the introduction of isobaric laparoscopy using abdominal wall lifting, this procedure can be performed using conventional surgical instruments introduced through small abdominal incisions. The aim of this study was to evaluate the feasibility, reproducibility, and safety of isobaric laparoscopic myomectomy for very large myomas  $\geq 10$  cm using a subcutaneous abdominal wall-lifting device.

**Methods:** A series of 24 consecutive patients with at least 1 symptomatic myoma  $\geq 10$  cm underwent a gasless laparoscopic myomectomy with the Laparotenser device. Conventional long laparotomy instruments were used.

**Results:** Gasless laparoscopic myomectomy was successful in all 24 consecutive patients. The size of the dominant myoma varied from 10 cm to 20 cm. The median operating time was 93 minutes. The median postoperative drop in hemoglobin was 2.8 g/dL. No surgical complications occurred. The median hospital stay was 2.8 days.

**Conclusion:** Gasless laparoscopic myomectomy is feasible, reproducible, and safe for removing very large myomas. Therefore, it can represent an excellent option for the minimally invasive removal of very large myomas.

**Key Words:** Very large myomas, Isobaric gasless laparoscopy, Myomectomy, Subcutaneous abdominal wall lifting device.

## INTRODUCTION

Uterine myomectomy is the preferred treatment for women who desire to preserve their reproductive apparatus. It has been documented that the laparoscopic approach offers several advantages in opposition to laparotomy, such as shorter hospitalization, reduced postoperative pain, and lower risk of postoperative adhesions.<sup>1,2</sup> However, it has been reported that laparoscopic myomectomy for large myomas ( $\geq 8$  cm) is hindered by several factors, such as their more difficult cleavage, the increase in operative time, the risk of perioperative bleeding, the risk of conversion to laparotomy.<sup>3</sup>

Generally, an analysis of the main reports about laparoscopic myomectomy demonstrates that the procedure is used more frequently for small- and medium-sized myomas (average diameter, 5 cm).<sup>4-11</sup> Reports of only a few series on laparoscopic removal of large myomas have been published.<sup>7,12,13</sup>

Since the more recent introduction of isobaric laparoscopy using abdominal wall lifting, the first reports on gasless laparoscopic myomectomy have been published.<sup>14,15</sup> This procedure, which can also be performed with the patient under local and regional (epidural or spinal) rather than general anesthesia, can be performed using conventional surgical instruments introduced through small abdominal incisions. This opportunity can allow removal of uterine myomas more rapidly and safely, as in laparotomy.

The aim of this study was to evaluate the feasibility, reproducibility, and safety of isobaric laparoscopic myomectomy for very large myomas  $\geq 10$  cm using a subcutaneous abdominal wall-lifting device.

## METHODS

A series of 24 consecutive women with at least 1 large symptomatic subserosal or intramural uterine myoma  $\geq 10$  cm underwent an isobaric laparoscopic myomectomy. The indications for surgery included pelvic pain, lower abdominal discomfort, abnormal uterine bleeding, menometrorrhagia, infertility, and pressure symptoms from a pelvic mass. Some women exhibited more than 1 indication. Fifteen women wished to preserve fertility be-

Unit of Gynecology and Obstetrics, International School of Gynaecological Endoscopy, 'S. Pio X' Hospital, Milan, Italy (Drs Damiani, Melgrati).

Section of Gynecology and Obstetrics, Department of Surgery, School of Medicine, Hospital University 'Tor Vergata' of Rome, Rome, Italy (Drs Marziali, Sesti, Piccione).

Address reprint requests to: Emilio Piccione, MD, Section of Gynecology and Obstetrics, Department of Surgery, Hospital University 'Tor Vergata' of Rome, Viale Oxford 81, 00133 Rome, Italy. Telephone: 39 06 20 900 161, Fax: 39 06 20 900 161, E-mail: clinica.ostetrica.ginecologica@med.uniroma2.it

© 2005 by JSLS, *Journal of the Society of Laparoendoscopic Surgeons*. Published by the Society of Laparoendoscopic Surgeons, Inc.

cause they wanted a child; the remaining 11 preferred in any case to preserve the uterus. Preoperative evaluation comprised obtaining hemoglobin and hematocrit levels, bimanual examination, abdominal and transvaginal sonography, and hysteroscopic examination of the uterine cavity. Gonadotropin releasing hormones agonists (GnRH-a) were prescribed only in those cases where anemia and low hematocrit due to excessive uterine bleeding were present. Treatment consisted of intramuscular administration of depot triptorelin every 4 weeks for 3 months.

Procedures were performed with the patients in the Trendelenburg position up to 30 degrees. Uterine cannulation was always used to achieve optimal exposure of the myoma. The surgical technique was always the same. Initially, subcutaneous lifting of the anterior abdominal wall was obtained by using the Laparotenser device (Lucini Surgical Concept, Milan, Italy). Two curved "pluriplan" needles with blunt tips were introduced subcutaneously through 2 very small (2 mm) pubic skin incisions. They were suspended from a mechanical arm attached to a rigid pillar, and the arm was then elevated as far as necessary to obtain optimal exposure. Successively, primary access was achieved by insertion of a 10-mm to 11-mm trocar through a vertical intraumbilical incision after lifting the abdominal wall with the Laparotenser. Under direct visualization, 2 lower incisions lateral to the rectus muscles were made without using trocars. On the right side, the lower incision was 15 mm (at most, up to 20 mm); on the left, it was 10 mm. Conventional long laparotomy instruments were used. The sole laparoscopic instruments used were the irrigation-suction cannula and the bipolar cautery. The ancillary right access permitted the insertion of  $\leq 3$  instruments; the left permitted insertion of 2 instruments.

Hysterotomy was performed transversally on the prominent part of the principal myoma along its maximum diameter using a low voltage electrode (monopolar scissors or hook). Hemostasis of the smallest intramyometrial vessels was achieved progressively using precise bipolar coagulation. Sharp dissection with Metzenbaum scissors allowed creation of the avascular cleavage plane separating the tumor and the surrounding myometrium. Enucleation was then executed by traction on the myoma with 2 strong Tenaculum clamps, associated with countertraction on the uterus with narrow ring forceps that facilitated dissection. The grasped myoma was then pulled hard toward the anterior abdominal wall or upward. The connective tracts adhering to the myoma were coagulated and sectioned with conventional scissors. Similarly, the major

vessels afferent to the myoma were clamped with conventional instruments and coagulated. The bed of the myomectomy was usually free of bleeding because great care had been taken in achieving hemostasis.

The uterine defect was repaired, using a conventional long needle holder, in 2 continuous layers with polyglactin 25, a synthetic adsorbable, monofilament suture, 135-cm long, mounted on a 39-mm curved needle with atraumatic tip. The suturing was begun at the right superior edge of the hysterotomy area and was pushed into the myometrium towards the opposite side. In succession, the level of the left inferior edge was arrived at, and the second continuous serosa-to-serosa suturing was completed from the left side toward the right one up to the apex. At the level of the right apex, intracorporeal knot tying was used to secure the suture ends with the aid of the index finger, introduced through the ancillary right access.

The myomas were extracted from the abdominal cavity by morcellation with scissors or a scalpel. The myoma was grasped by 2 opposite Tenaculum clamps and converted into thin strips of tissue by using conventional scissors or knives. The myoma strips were removed through the ancillary right port.

## RESULTS

Isobaric laparoscopic myomectomy using the Laparotenser device was successful in all 24 consecutive patients. The mean age of the women was 41 years (range, 30 to 49). The number of myomas removed from each patient ranged from 1 to 4 (average, 2.3). In 5 cases (20.8%), multiple myomectomies were performed. The location of the principal myoma was intramural in 10 patients (41.6%) and subserosal in 14 (58.3%). The size of the dominant myoma varied from 10 cm to 20 cm (average, 11.0 cm). The site of the major myoma was anterior in 8 patients, fundal in 9, and posterior in 7. The median postoperative drop in hemoglobin was 2.8 g/dL (range, 2.3 to 4.3 g/dL). No transfusions were required. The mean operating time was 93 minutes (range, 55 to 150). The mean inserting Laparotenser time was 3.5 minutes (range, 2 to 5). The hospital stay was 1 day to 3 days (average, 1.9).

No significant operative benefit (reduced blood loss during surgery, lower operative time) was found in those cases where gonadotropin therapy was administered. No intraoperative complication occurred, and no repeat operation was necessary. The only postoperative complication observed was fever  $>38^{\circ}\text{C}$  in 5 cases. Fever regressed

in 1 day to 3 days through antibiotic and NSAID administration. No infectious complications (urinary tract, endometritis, pelvi-peritonitis) occurred. No injury to epigastric vessels was observed. No conversion to laparotomy or hysterectomy was necessary. No anesthesia complications occurred. No patient complained of significant abdominal postoperative discomfort, secondary to the abdominal lifting. Right shoulder pain, a common finding after pneumoperitoneum, was observed in no patient. No postoperative herniation was found.

At the 12-month postoperative follow-up, the main symptoms before surgery had disappeared.

## DISCUSSION

Disagreement still exists concerning the usefulness of laparoscopic myomectomy in treating patients with large symptomatic leiomyoma. Actually, laparoscopic myomectomy using pneumoperitoneum for large intramural myomas is considered a difficult and time-consuming procedure, requiring great skill to move a large uterus; to locate, grasp, enucleate, and remove a bulky myoma from the abdominal cavity; to achieve adequate hemostasis; and to repair the ample uterine defect.<sup>16</sup>

In the literature, a few reports are available on removal of large myomas by laparoscopy with pneumoperitoneum. Malzoni et al<sup>17</sup> reported average sized 7.8-cm myomas with a range of 5 cm to 18cm, a 1.39% laparotomy conversion rate, an operating time ranging from 58 minutes to 180 minutes with an average of 95 minutes, and 2.08% overall complication rate. Sinha et al<sup>18</sup> reported on 51 women with at least 1 myoma larger than 9cm. The largest myoma removed was 21 cm. Mean myoma weight was 698.47 g (range, 210 to 3400). Mean operating time was 136.67 minutes (range, 80 to 270). Mean blood loss was 322.16 mL (range, 100 to 2000). One patient developed a broad ligament hematoma, 2 developed postoperative fever, and 1 underwent open subtotal hysterectomy 9 hours after surgery for dilutional coagulopathy. The authors concluded that myomectomy by laparoscopy is a safe alternative to laparotomy for very large myomas. Takeuchi and Kuwatsuru<sup>19</sup> found that when the myomas were larger than 10 cm, the blood loss and operating time were increased. However, the number of myomas did not correlate with blood loss. They concluded that laparoscopic myomectomy appears to offer a number of advantages if the myoma is not larger than 10 cm.

Therefore, it was suggested that myomas should not exceed 8 cm maximum in diameter, because their cleavage is more difficult, the operating time increases, and the risk

of perioperative bleeding is elevated.<sup>3</sup> Hence, large intramural myomas >8 cm are usually removed by laparotomy.

To overcome the limits associated with laparoscopic myomectomy using pneumoperitoneum and to preserve the advantages of the minimally invasive surgery, isobaric (gasless) laparoscopic myomectomy was developed. Chang et al<sup>4</sup> reported preliminary results on a small series of patients. The size of the myomas ranged from 6.5cm to 12 cm (mean, 7.96). Mean operative time was 104 minutes (range, 78 to 165). The average blood loss was 201 mL (range, 90 to 580). No major complication occurred during the operation or follow-up.<sup>5</sup> Conversion to laparotomy was necessary in 1 patient because of moderate pelvic adhesions following previous abdominal surgery. They concluded that gasless laparoscopy might be useful in treating large symptomatic leiomyomas that would otherwise require more extensive surgery.

In accordance with our previous article,<sup>15</sup> the present study has confirmed that gasless laparoscopic myomectomy also allows the removal of very large myomas >10 cm through a minimally invasive procedure. Surgery was completed in all 24 consecutive patients. No conversion to laparotomy or hysterectomy was necessary. All parameters analyzed (operating time, blood loss, hospital stay) were optimal, despite sometimes having to deal with extremely large myomas (one myoma was 20 cm). Because we have found no significant operative benefit (reduced blood loss during surgery, lower operative time) in those patients preoperatively treated with GnRH agonists, and their use may increase the difficulty of fibroid enucleation, gonadotropin therapy should not be routinely used except in cases of preoperative anemia.

These satisfactory results can be explained by the advantages of the gasless laparoscopy over the conventional laparoscopy using pneumoperitoneum. First, the adverse effects and potential risks of CO<sub>2</sub> insufflation are eliminated. Second, because the peritoneal cavity does not need to be sealed airtight, conventional long laparotomy instruments, such as tissue clamps, Tenaculum clamps, needle holders, knives, and scissors can be utilized. This facilitates several steps of the procedure. For example, enucleation of the myoma with Tenaculum clamps exerting countertraction on the uterine edge with narrow ring forceps is simple and quick. One of the main advantages is the uterine repair, which in laparoscopy with pneumoperitoneum is usually bothersome and protracted for the difficulties associated with intracorporeal suture techniques. Instead, applying the conventional curved needle



deeply into the myometrium of the hysterotomy area with the laparotomy needle holder is trouble-free and fast. In this manner, we have quickly performed a double-layer continuous, not intersecting, closure. The first layer was passed deeply through the myometrium; the second was a continuous introflexing serosa-to-serosa suturing. Intra-corporeal knot tying was used to secure the suture ends with the aid of the index finger, introduced through the ancillary right access. Therefore, this closure warranted an optimal hemostasis and strength of the uterine scar.

A third advantage is the reduction in operative costs. Expensive, specialized laparoscopic instruments are not needed. In addition, the operating times are decreased because an optimal view can be maintained during irrigation-suction, the repair of the uterine defect is less time consuming and myoma morcellation by scissors or knives is faster.

Therefore, this procedure associates the advantages of laparoscopy and minimal access surgery with those of using the laparotomic instruments that are more reliable for uterine closure. In fact, when performing laparoscopic myomectomy, particular care must be given to the uterine closure, because a meticulous repair of the myometrium is essential to minimize the risk of uterine rupture during a subsequent pregnancy, labor, and delivery. So, myomectomy is just the gynecological surgery that can benefit more from this technique.

However, some criticisms have been made of the gasless laparoscopy. Many laparoscopists are worried about the increased postoperative pain, the need for additional abdominal incisions, the time required for the assemblage of the abdominal lifting system. But in the present series, no patient complained of significant abdominal postoperative discomfort, secondary to the abdominal lifting. The additional suprapubic skin incisions required for the subcutaneous introduction of the 2 curved needles with the blunt tips of the Laparotenser were very small (2 mm) and needed no suturing. Lastly, the Laparotenser can be effortlessly assembled. In our series, its mean inserting time was 3.5 minutes.

Other reports have been published on the use of abdominal lifting devices for gasless laparoscopic surgery.<sup>14,20–24</sup> Problems inherent in their use included suboptimal exposure in pelvic surgery because of a “tenting” effect and possible ischemic injury to the abdominal wall muscles from the retractor. Another kind of device consisted of subcutaneous long wires.<sup>25–27</sup> The Laparotenser utilizes this concept and provides subcutaneous lifting, which avoids muscle injury and has less “tenting” effect. In our

study, operative exposure was always as optimal as that achieved by pneumoperitoneum, in contrast to that observed by Chang et al<sup>14</sup> using an intraperitoneal lifting system. Therefore, the Laparotenser appears to be a reliable, effective, and safe device, achieving a larger internal operation theatre and avoiding local microtrauma and tissue overtension.

## CONCLUSION

Our results show that gasless laparoscopic myomectomy for removal of very large myomas using the subcutaneous lifting system Laparotenser is feasible, reproducible, and safe. It appears to offer several advantages over laparoscopy with pneumoperitoneum, such as elimination of the adverse effects and potential risks associated with CO<sub>2</sub> insufflation, use of conventional long laparotomy instruments that facilitate several steps of the procedure, reduction of the operative times and costs. Therefore, it can represent an excellent option for the minimally invasive removal of very large myomas, as an alternative to more aggressive surgery. However, further controlled studies on more extensive series are needed to better define its indications and long-term results.

## References:

1. Dubuisson J-B, Fauconnier A, Chapron C, Kreiker G, Norgaard C. Second look after laparoscopic myomectomy. *Hum Reprod.* 1998;13:2102–2106.
2. Mais V, Ajossa S, Guerriero S, Mascia M, Solla E, Melis GB. Laparoscopic versus abdominal myomectomy: a prospective, randomized trial to evaluate benefits in early outcome. *Am J Obstet Gynecol.* 1996;174:654–658.
3. Dubuisson J-B, Fauconnier A, Babaki-Fard K, Chapron C. Laparoscopic myomectomy: a current view. *Hum Reprod Update.* 2000;6:588–594.
4. Darai E, Deval B, Darles C, Benifla JL, Guglielmina JN, Madelenat P. Myomectomie: coelioscopie ou laparotomie. *Contracept Fertil Sex.* 1996;24:751–756.
5. Dubuisson J-B, Fauconnier A, Deffarges J-V, Norgaard C, Kreiker G, Chapron C. Pregnancy outcome and deliveries following laparoscopic myomectomy. *Hum Reprod.* 2000;15:869–873.
6. Landi S, Zoccoletti R, Ferrari L, Minelli L. Laparoscopic myomectomy: technique, complications, and ultrasound scan evaluations. *J Am Assoc Gynecol Laparosc.* 2001;8:231–240.
7. Mettler L, Alvarez-Rodas E, Semm K. Myomectomy by laparoscopy: a report of 482 cases. *Gynaecol Endosc.* 1995;4:259–264.
8. Reich H. Laparoscopic myomectomy. *Obstet Gynecol Clin North Am.* 1995;22:757–780.

9. Ribeiro SC, Reich H, Rosenberg J, Guglielminetti E, Vidali A. Laparoscopic myomectomy and pregnancy outcome in infertile patients. [Fertil Steril. 1999;71:571–574.](#)
10. Rossetti A, Sizzi O, Scranna L, Mancuso S, Lanzone A. Fertility outcome: long-term results after laparoscopic myomectomy. [Gynecol Endocrinol. 2001;15:129–134.](#)
11. Seiner P, Arisio R, Decko A, Farina C, Crana F. Laparoscopic myomectomy: indications, surgical technique and complications. [Hum Reprod. 1997;12:1927–1930.](#)
12. Adamian LV, Kulakov VI, Kiselev SI, Murashko AV. Laparoscopic Myomectomy in Treatment of Large Myomas. [J Am Assoc Gynecol Laparosc. 1996;3\(4, Suppl\):S1.](#)
13. Stringer NH. Laparoscopic myomectomy in African-American women. [J Am Assoc Gynecol Laparosc. 1996;3:375–381.](#)
14. Chang FH, Soong YK, Cheng PJ, et al. Laparoscopic myomectomy of large symptomatic leiomyoma using airlift gasless laparoscopy: a preliminary report. [Hum Reprod. 1996;11:1427–1432.](#)
15. Damiani A, Melgrati L, Marziali M, Sesti F. Gasless laparoscopic myomectomy. Indications, surgical technique and advantages of a new procedure for removing uterine leiomyomas. [J Reprod Med. 2003;48:792–798.](#)
16. Nezhat C, Nezhat F, Bess O, Nezhat CH, Mashiach R. Laparoscopically assisted myomectomy: a report of a new technique in 57 cases. [Int J Fertil Menopausal Stud. 1994;39:39–44.](#)
17. Malzoni M, Rotond M, Perone C, et al. Fertility after laparoscopic myomectomy of large uterine myomas: operative technique and preliminary results. [Eur J Gynaecol Oncol. 2003;24:79–82.](#)
18. Sinha R, Hegde A, Warty N, Patil N. Laparoscopic excision of very large myomas. [J Am Assoc Gynecol Laparosc. 2003;10:461–468.](#)
19. Takeuchi H, Kuwatsuru R. The indications, surgical techniques, and limitations of laparoscopic myomectomy. [JSLs. 2003;7:89–95.](#)
20. Banting S, Shimi S, Vander Velpen G, Cuschieri A. Abdominal wall lift. Low-pressure pneumoperitoneum laparoscopic surgery. [Surg Endosc. 1993;7:57–59.](#)
21. Brams DM, Cardoza M, Smith RS. Laparoscopic repair of traumatic gastric perforation using a gasless technique. [J Laparoendosc Surg. 1993;3:587–591.](#)
22. Gazayerli MM. The Gazayerli endoscopic retractor model 1. [Surg Laparosc Endosc. 1991;1:98–100.](#)
23. Smith RS, Fry WR, Tsoi EK, et al. Gasless laparoscopy and conventional instruments. The next phase of minimally invasive surgery. [Arch Surg. 1993;128:1102–1107.](#)
24. Weaver DW. Gasless laparoscopy for complex surgical procedures. [Int Surg. 1994;79:314–316.](#)
25. Angelini L, Lirici MM, Papaspyropoulos V, Sossi FL. Combination of subcutaneous abdominal wall retraction and optical trocar to minimize pneumoperitoneum-related effects and needle and trocar injuries in laparoscopic surgery. [Surg Endosc. 1997;11:1006–1009.](#)
26. Hashimoto D, Nayeem SA, Kajiwara S, Hoshino T. Abdominal wall lifting with subcutaneous wiring: an experience of 50 cases of laparoscopic cholecystectomy without pneumoperitoneum. [Surg Today. 1993;23:786–790.](#)
27. Vezakis A, Davides D, Gibson JS, et al. Randomized comparison between low-pressure laparoscopic cholecystectomy and gasless laparoscopic cholecystectomy. [Surg Endosc. 1999;13:890–893.](#)

# Isobaric (gasless) laparoscopic myomectomy during pregnancy

Luigi Melgrati, MD, Alfredo Damiani, MD, Gianalfredo Franzoni, MD, Massimiliano Marziali, MD, and Francesco Sesti, MD

*From the Unit of Gynecology and Obstetrics, International School of Gynecological Endoscopy, S. Pio X Hospital (Drs. Melgrati, Damiani, and Franzoni), Milan; and the Section of Gynecology and Obstetrics, Department of Surgery, School of Medicine, Hospital University Tor Vergata of Rome (Drs. Marziali and Sesti), Rome, Italy.*

## KEY WORDS:

Isobaric gasless laparoscopy;  
Subcutaneous abdominal wall lifting;  
Myomectomy;  
Pregnancy

**Abstract.** We report on the first case of an isobaric (gasless) laparoscopic myomectomy during the second trimester of pregnancy. Our patient had acute abdominal pain that did not respond to medical management. The procedure was performed under spinal anesthesia with conscious sedation. The remainder of the pregnancy was unremarkable. We believe that surgical management of uterine leiomyoma during pregnancy may be successfully performed in carefully selected patients. Laparotomy can be avoided, and pregnant patients can be managed safely by operative laparoscopy. With isobaric laparoscopy, the adverse effects and potential risks of CO<sub>2</sub> insufflation are eliminated. The procedure can be performed under loco-regional anesthesia. The uterine closure can be performed safely and quickly as in laparotomy.

© 2005 AAGL. All rights reserved.

Although leiomyomas usually remain asymptomatic during pregnancy, they may complicate its course. Complications during pregnancy that require surgical intervention are due to increase in lesion size causing discomfort and/or severe abdominal pain that does not respond to medical therapy.

We report on a case of isobaric (gasless) laparoscopic myomectomy during the second trimester of pregnancy in a woman with acute abdominal pain that did not respond to medical management. We discuss the effectiveness, safety, complications, and outcome of pregnancy after myomectomy performed during pregnancy.

## Case report

A 29-year-old primiparous woman at 24 weeks' gestation had acute abdominal pain that did not respond to medical management with analgesic or nonsteroidal anti-inflammatory drugs. Her temperature was 38.1° C. Clinical examination showed a subacute abdomen with periumbilical Blumberg's sign positive. Rebound pelvic examination was painful. Ultrasound revealed a single uterine viable pregnancy corresponding to date and a subserosal myoma measuring 7 × 7 cm on the uterine fundus. Because we suspected torsion or necrosis of the myoma, an isobaric laparoscopy was performed using the Laparotenser device (Lucini Surgical Concept, Milan, Italy). The procedure was performed under spinal anesthesia with conscious sedation. A partially necrotic uterine leiomyoma was detected. It had a large base on the uterine fundus without torsion. Using the surgical technique previously described,<sup>1</sup> the entire myoma was removed and successively extracted from the abdominal cavity by morcellation with scalpel. Monopolar and bipolar electrosurgery were not used. The uterine defect was repaired, using a conventional long needle holder, in one

---

Corresponding author: Francesco Sesti, MD, Section of Gynecology and Obstetrics, Department of Surgery, Hospital University Tor Vergata of Rome, Viale Oxford 81, 00133 Rome, Italy.

E-mail: clinica.ostetrica.ginecologica@med.uniroma2.it

Submitted October 21, 2004. Accepted for publication February 7, 2005.

layer with continuous closure with a synthetic absorbable monofilament suture, mounted on a curved needle with a blunt tip. Operating time was 40 minutes. Intraoperative blood loss was 50 mL. No intraoperative complications occurred, and there were no anesthesia-related complications. Histologic examination confirmed the diagnosis of a partially degenerated uterine leiomyoma. The postoperative course was normal, and the woman was discharged the first postoperative day. The remainder of the pregnancy was unremarkable. At 39 weeks, the woman began a normal labor and had a spontaneous vaginal delivery. The baby's Apgar score was 9/9. The puerperium was normal.

## Discussion

A retrospective analysis of 18 patients who underwent myomectomy between the 6th and 24th weeks of pregnancy suggests that myomectomy during pregnancy may be considered safe in selected patients. Moreover, it permits good pregnancy outcome with healthy babies delivered at term.<sup>2</sup>

Laparotomy can be avoided, and pregnant patients can be managed safely by operative laparoscopy, with shorter hospital stays. The most common indications for laparoscopy in pregnancy are cholelithiasis, appendicitis, persistent ovarian cyst, and adnexal torsion. The increasing number of reported cases suggests that laparoscopic surgery appears to be safe in the first two trimesters with a good maternal and fetal outcome. Surgical management of uterine leiomyoma during pregnancy may be successfully performed in carefully selected patients.<sup>3</sup> However, it can be complicated by injury to the gravid uterus, resulting in pregnancy loss; and the surgeon must be skilled in advanced techniques of laparoscopic surgery.<sup>3</sup>

More recently, isobaric laparoscopy using abdominal wall lifting has been developed to overcome the adverse effects of pneumoperitoneum. Moreover, it is possible to perform the surgical procedures under loco-regional (peridural or spinal) rather than general anesthesia.

In the literature, there are some reports on myomectomy that has been performed during pregnancy by laparotomy<sup>2,4,5</sup> or conventional laparoscopy with pneumoperitoneum.<sup>6,7</sup> Up to now, the unique reports on gasless laparoscopy during pregnancy pertained to adnexal surgery and cholecystectomy.<sup>8,9</sup> To our knowledge, an isobaric laparoscopic myomectomy during pregnancy has not previously been reported.

Isobaric laparoscopy offers several advantages over conventional laparoscopy with pneumoperitoneum. The adverse effects and potential risks of CO<sub>2</sub> insufflation are eliminated. Also, because the peritoneal cavity does not need to be sealed airtight, conventional long laparotomy instruments, such as tissue clamps, tenaculum clamps, needle holders, knives, and scissors can be used. This facilitates several steps of the procedure. One of the main advantages is in uterine repair because laparoscopy with pneumoperi-

toneum usually is problematic and prolonged due to the difficulties associated with intracorporeal suture techniques. Instead, applying the conventional curved needle deeply into the myometrium of the hysterotomy area with the laparotomy needle holder is easier and faster. Another advantage is the reduction in operative costs. Expensive, specialized laparoscopic instruments are not needed. In addition, operating times are decreased because optimal view can be maintained during irrigation and suction, the repair of the uterine defect is less time consuming, and myoma morcellation by scissors or knives is faster. This simple and easy technique requires a short learning curve compared with laparoscopic myomectomy with pneumoperitoneum, which requires considerable surgical skill and experience.

One of the major concerns about laparoscopic myomectomy is the risk of uterine rupture during pregnancy or labor due to insufficient closure or healing of a laparoscopic myomectomy incision. However, few clinical series have found uterine rupture during pregnancy. In an observational study of laparoscopic myomectomy,<sup>10</sup> among the 100 patients who had delivery, there were three instances of spontaneous uterine rupture. But only one of these uterine ruptures occurred at the scar. Seventy-two patients (72.0%) had trials of labor. Of these, 58 (80.6%) were delivered vaginally. There was no uterine rupture during the trials of labor. In our previous prospective study on gasless laparoscopic myomectomy,<sup>1</sup> among the 48 women who had delivery, 35 (72.9%) underwent elective caesarean section at term, and 13 (27.1%) had spontaneous vaginal deliveries. No cases of uterine rupture during pregnancy or labor were observed. In a recent review, the risk of uterine rupture during pregnancy was estimated to be less than 1% if the uterus was closed appropriately.<sup>11</sup> When performing laparoscopic myomectomy, particular care must be given to uterine closure, because a meticulous repair of the myometrium is essential to minimize the risk of uterine rupture during pregnancy, labor, and delivery.

As previously emphasized,<sup>5</sup> the augmented vascularization and tissue impedance of the gravid uterus can amplify the risk of electrosurgical damage. Therefore, we avoided the use of monopolar and bipolar electrosurgery for the myoma resection, and no complication was registered during the remainder of pregnancy, spontaneous labor, and vaginal delivery.

## Conclusion

The safest time to perform laparoscopic surgery in pregnancy is during the second trimester. However, it can be complicated by injury to the gravid uterus, resulting in pregnancy loss, especially for leiomyoma. If further studies confirm our experience, laparoscopic myomectomy should be considered a minimally invasive alternative to traditional laparotomy for selected patients when myomectomy during pregnancy is necessary. Isobaric laparoscopy may represent



a valid option together with conventional laparoscopy. With gasless laparoscopy, the adverse effects and potential risks of CO<sub>2</sub> insufflation are eliminated. The procedure can be performed under loco-regional anesthesia. Uterine closure can be performed safely and quickly such as in laparotomy.

## References

1. Damiani A, Melgrati L, Marziali M, et al. Gasless laparoscopic myomectomy: indications, surgical technique, and advantages of a new procedure for removing uterine leiomyomas. *J Reprod Med.* 2003;48:792-798.
2. De Carolis S, Fatigante G, Ferrazzani S, et al. Uterine myomectomy in pregnant women. *Fetal Diagn Ther.* 2001;16:116-119.
3. Al-Fozan H, Tulandi T. Safety and risks of laparoscopy in pregnancy. *Curr Opin Obstet Gynecol.* 2002;14:375-379.
4. Lolis DE, Kalantaridou SN, Makrydimas G, et al. Successful myomectomy during pregnancy. *Hum Reprod.* 2003;18:1699-1702.
5. Celik C, Acar A, Cicek N, et al. Can myomectomy be performed during pregnancy? *Gynecol Obstet Invest.* 2002;53:79-83.
6. Pelosi MA, Pelosi MA 3rd, Giblin S. Laparoscopic removal of a 1500-g symptomatic myoma during the second trimester of pregnancy. *J Am Assoc Gynecol Laparosc.* 1995;2:457-462.
7. Sentilhes L, Sergent F, Verspyck E, et al. Laparoscopic myomectomy during pregnancy resulting in septic necrosis of the myometrium. *BJOG.* 2003;110:876-878.
8. Romer T, Bojahr B, Schwesinger G, et al. Treatment of a torqued hematosalpinx in the thirteenth week of pregnancy using gasless laparoscopy. *J Am Assoc Gynecol Laparosc.* 2002;9:89-92.
9. Iafrati MD, Yarnell R, Schwaitzberg SD. Gasless laparoscopic cholecystectomy in pregnancy. *J Laparoendosc Surg.* 1995;5:127-130.
10. Dubuisson JB, Fauconnier A, Deffarges JV, et al. Pregnancy outcome and deliveries following laparoscopic myomectomy. *Hum Reprod.* 2000;15:869-873.
11. Hurst BS, Matthews ML, Marshburn PB. Laparoscopic myomectomy for symptomatic uterine myomas. *Fertil Steril.* 2005;83:1-23.

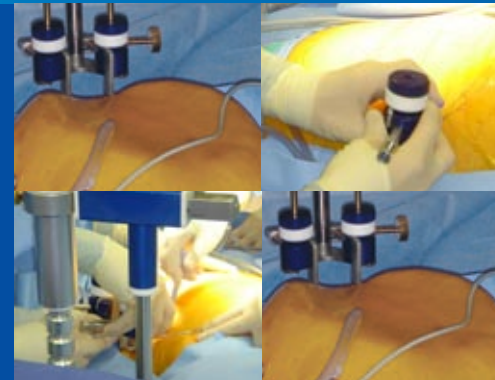
# LAPARO TENSER™

## COMPANY

Lucini Surgical Concept was founded in 1959, the firm came to life with the stamp of craftsmen, in the sense that every product produced was unique and highly specific. Nearly every product was studied and produced to satisfy the specific needs of doctors, surgeons and hospital administrators. Every product became the solution to a problem which the careful operator needed to resolve. Each product was a work of art and the laboratory was in a small cellar in Milan's old city centre.

The success of Lucini Surgical Concept's products guided the firm's evolution. Expanding markets, vivid technological competition and the need to unite and control the output, by now in terms of mass-production, led to the opening of a 10,000 sq ft factory on the outskirts of Milan.

The fruit of this investment and research is characterized in the new line of products which represents the synthesis of 50 years of experience as high-tech craftsmen. The Lucini family continues to represent the direction of the new company, as a guarantee of the corporate values and of the passion that has distinguished their entrepreneurial activities.



### Videos of Procedures Using LaparoTenser

- [▶ Video 1 Bariatric](#)
- [▶ Video 2 Gynecology](#)
- [▶ Video 3 Lap Chole](#)
- [▶ Video 4 Urology](#)

## The Lucini Philosophy

▶ If you want a product to sell, you should put forth its worth and demonstrate that its quality is impeccable.

If you are interested in buying a product, you should carefully evaluate your real needs and be sure that the product can satisfy them.

He who sells honestly, proposes and emphasizes a reality.

He who buys prudently is aware of its value...

To sell honestly and buy prudently presupposes the existence of a useful reality and agreement.

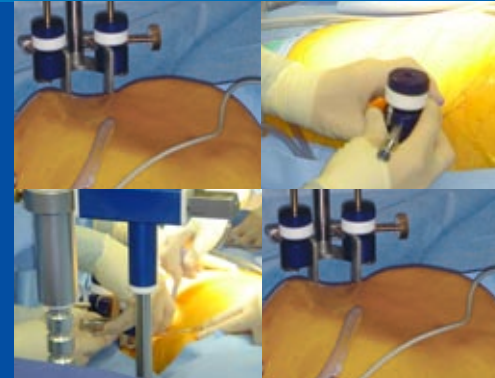
If you want to produce, you must plan on intending to realize an idea, you must possess the intuition to capture it, the will to pursue it, the technique to follow it through and the honesty to evaluate the product is really the realization of your idea and above all if the idea once "real" is useful.

Idea, intuition, will, technique and honesty are paradigms which inspire our lives, our ideas and our products.





*Flavio Lucini*

# LAPARO TENSER™

## ORDERING AND CONTACTS



### Videos of Procedures Using LaparoTenser

-  Video 1 Bariatric
-  Video 2 Gynecology
-  Video 3 Lap Chole
-  Video 4 Urology

### World

#### Lucini Surgical Concept srl

Via E.Mattei 17/19

20037 Paderno Dugnano - Milano - Italy

Phone: +39 02 9186543

Fax: +39 02 9189185

Email: [info@lucinisurgicalconcept.com](mailto:info@lucinisurgicalconcept.com)

[www.lucinisurgicalconcept.com](http://www.lucinisurgicalconcept.com)

### USA

#### MedSurg Specialty Devices

633 Village Lane North

Mandeville, LA 70471

Phone: (800) 423-5244

[www.medsurgsd.com](http://www.medsurgsd.com)



#### Technical Questions?

Email: [info@lucinisurgicalconcept.com](mailto:info@lucinisurgicalconcept.com)

